

Case Report: Fungal Infections in the Normal Gingival Mucosa Affecting Oral Surgery

Fanny Margaretha Laihad^{1*}, Hery Supriyadi², Eddy Hermanto³
Monika Elidasari⁴, Soemartono⁵, Ghita Hadi Hollanda⁶

^{1*&2}Sub Department of Oral Surgery,
Naval Hospital dr. Ramelan Surabaya,
Indonesia.

¹⁻⁶Departement of Oral Surgery,
Dental Faculty,
Hang Tuah University, Surabaya,
Indonesia.

Accepted 7 December, 2017.

ABSTRACT

Background: Fungal infections is difficult to detect. to diagnose and to treat because there was no clinical sign in oral cavity. Often regarded as a normal flora, the fungus in the oral cavity is less calculated in performing oral surgery, but there are case reports stating that patients infected with oral fungus have a history of previous trauma due to self-extraction of a tooth or injection. **Purpose:** To study the presence of fungal infections in the normal gingival mucosa affecting oral surgery. **Case report:** One case of tooth extraction with complications in immunocompromised patient and two cases of odontectomy in young and healthy patients. Despite prior premedication of antibiotics and analgesics, the minor operation has to be postponed because the patients feel severe pain once the gingival mucosa is touched and anesthesia is performed by injection. **Results:** There was a growth of fungus in the gingival mucosal after culturing and after being given anti-fungal therapy for 7 days, patients can be performed painless surgery. **Conclusion:** Need to be aware of the presence of fungal infection when performing surgery in the oral cavity especially in immunocompromised patients, also in healthy patients and the possibility of spreading the infection to other organs through blood vessel.

Keywords: Fungal infection, Normal gingival mucosa, Oral surgery.

1. Introduction

Fungi are a versatile group of microorganisms which can be freely present in the environment, have the ability to cause mild superficial infections to severe life threatening invasive infections but also as a part of the normal flora of human and animals (Ramani *et al*, 2013). Fungi are widespread and ubiquitous in the environment and diverse array of fungi can be found on mucous membranes of humans (Rickerts & Fredricks, 2012.). Fungi are saprophytic microorganisms which have evolved mechanisms to survive in the mammalian hosts. In systemic fungal infections the outcome of the disease depends more on the host factors rather than the fungal virulence. Immune response to fungal infections is a complex subject where in fungi invading goes unrecognized by the immune system and that invasive fungal infections can result in severe inflammatory reactions resulting in morbidity and mortality. Invasive fungal infections (IFIs) are those infections where fungi have invaded in to the deep tissues and have established themselves resulting in prolonged illness (Ramani *et al*, 2013). Invasive fungal infection (IFIs) is difficult to diagnose and therapy sometimes even misdiagnosed (Brown *et al*, 2012; Alfano *et al*, 2006). These infections are opportunistic, they occur when organisms to which we are frequently exposed gain entry to the body due to a decrease in host defenses (Fogarty *et al*, 2006) Fungi are opportunistic infectious agents and most of them are not usually pathogenic. But when they infect an immunocompromised host, can cause a wide range of diseases ranging from superficial to

disseminated infections involving the vital internal organs (Puebla, 2012). From being uncommon during the earlier part of the 20th century when the world was disturbed with bacterial epidemics, fungi have evolved as a major global health problem (Ramana *et al*, 2013). However, epidemiological data for fungal infections are notoriously poor because fungal infections are often misdiagnosed. Consequently, the calculations may significantly underestimate the true burden of invasive fungal disease (Brown *et al*, 2012). The rarity of this disease leads to difficulties in diagnosis and delays can result in poor prognosis (Alfano *et al*, 2006). Oral candidiasis is the most common human fungal infection (Akpan & Morgan, 2002).

Pandey *et al* (2011) report four cases of mucormycosis with exposed bone in the oral cavity and all the patients gave a history of previous trauma due to self-extraction of a tooth or injection. Laihad *et al* (2017) in the case of periodontitis suspected caused by fungal infection said that the patient had the symptoms like swelling with a rather hard consistency but no redness, no febris but very painful.

In this paper, 3 minor surgical cases had been delayed as the patients feel severe pain when the gingival mucosa was touched and injected for anesthesia even though the mucosa looks normal, no swelling, no color changes, no febris and normal functioning. Swabs were performed on the gingival mucosa, cultured and found fungi as a result. After being given

an antifungal for 7 days, the patients can be operated again painlessly.

2. Cases Report and Management

2.1 Case 1

A 53-year old female patient was referred by an internist for a tooth extraction of 22 and 24 that is gangrenous root in September 2017. Patient had a history of controlled diabetes, cardiovascular disease and already treated nasopharyngeal

cancer. Previously, patient had been given premedication cefadroksil 500 mg and mefenamic acid 500 mg. At the time of sterilization in the gingival mucosa prior to local anesthetic injection, the patient felt very painful when the gingival mucosa was touched. Tooth extraction was delayed and gingival swabs are performed to detect fungus in the oral cavity. In the result of culture, there is a growth of fungus and then the patient was given fluconazole 150 mg for 7 days. Furthermore, dental extraction with complications can be done safely without pain.

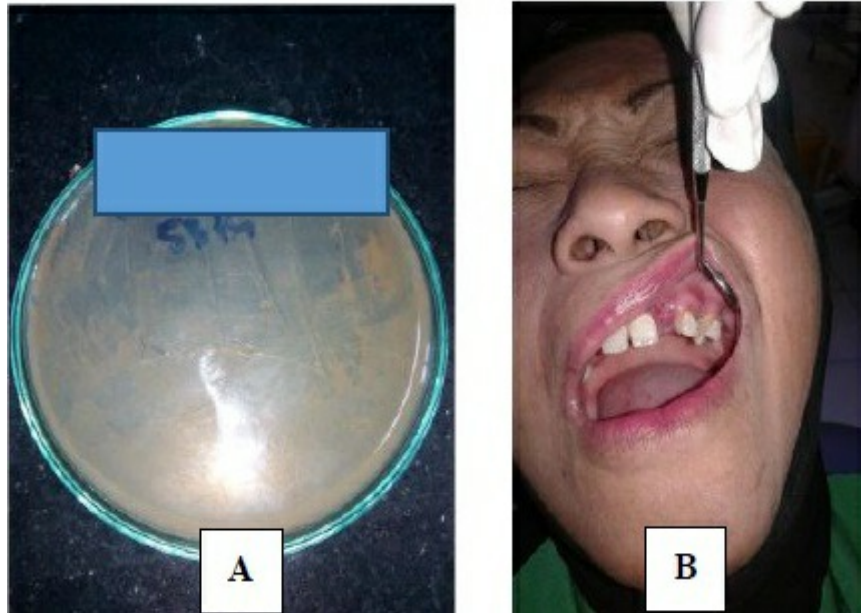


Figure 1: A. Culture Result; B. 1 week post dental extraction

2.2 Case 2

In September 2017, male patient, 22 year old student came to oral surgery clinic, Naval hospital dr. Ramelan Surabaya for odontectomy 38. From anamnesis, obtained the condition of a healthy patient and there is no systemic disease. Previously, he had been given premedication of cefadroksil 500 mg and mefenamic acid 500 mg. At the time of infiltration anesthesia is injected in the gingival mucosa of buccal portion, the patient feel very painful, as does the mandibular anesthesia. Although

anesthesia work well, the patient still complain of pain during incision, flap making and especially when drilled on the alveolar bone. The odontectomy was canceled and swabs are performed on the gingival mucosa to see if there was fungal growth. From fungal culture, the result was positive and suspected candida. After being given anti-fungal drug, fluconazole 150 mg for 7 days, odontectomy can be done without pain. The patient also informed the existence of wounds on the back of the left hand that won't heal and after being given the anti-fungus, it improved.

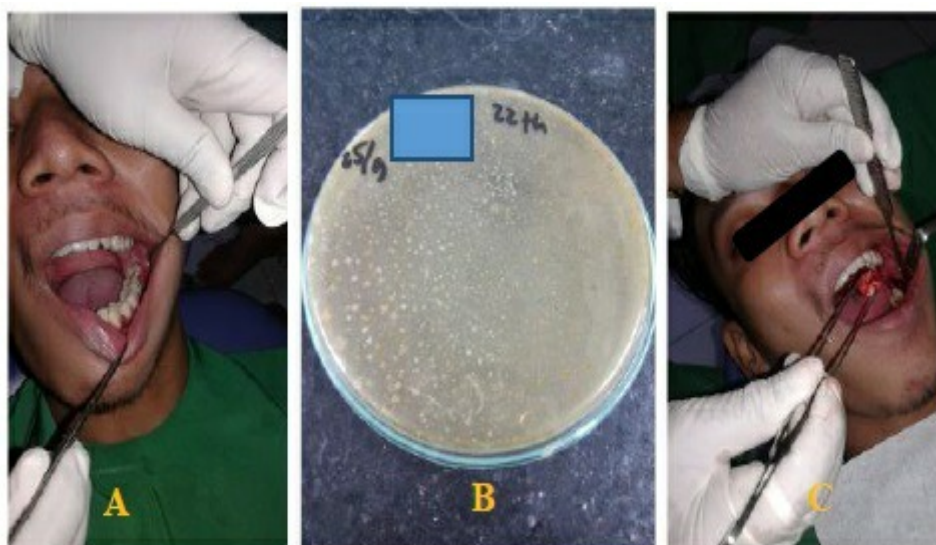


Figure 2: A. Delay operation; B. Culture Result; C. Successful Odontectomy

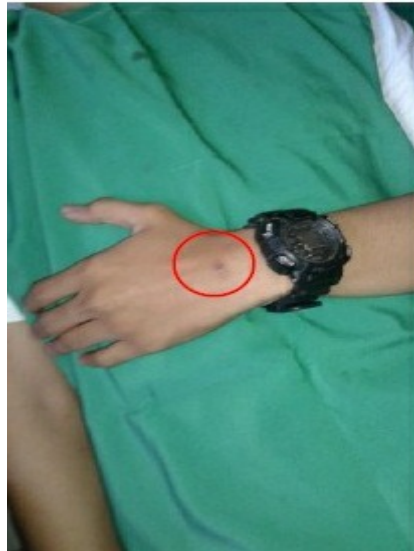

Figure 3: Wound on the back of the left hand

2.3 Case 3

A young 20-year-old female and healthy patient is already scheduled for a dental odontectomy 48 because of impaction in October 2017. When the gingival mucosa was to be sterilized with betadine solution before anesthesia, the patient felt severe pain when the gums were touched. From anamnesis it was found that patient often use antibiotics when

she is sick or felt unhealthy. A gingival mucosa swab was performed to detect oral fungal growth. Culture result indicates the growth of a suspected candida fungus. Such as the previous patients, she was given fluconazole 150 mg for 7 days with dose of 2 x 1 on the first day and 1 x 1 for the next day. After which the patient was able to be odontectomy safely without pain and could be controlled and the suturing was open 1 week later.

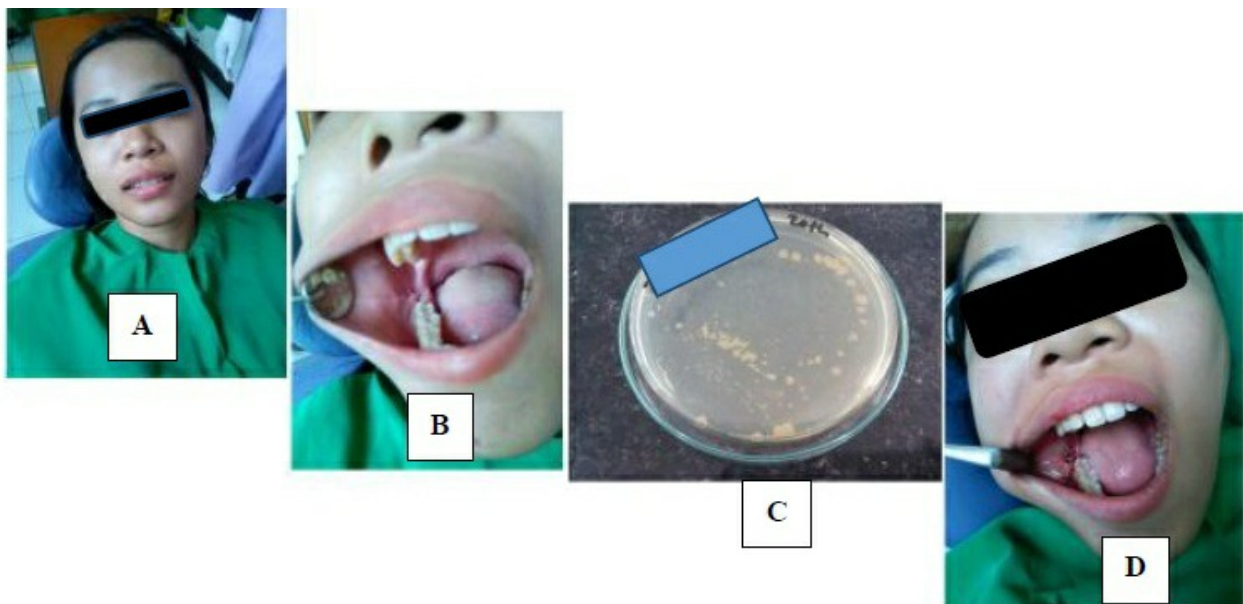


Figure 4: A. Extra-oral Image; B. Intra-oral Image; C. Culture Result; D. Post Odontectomy

3. Discussion

The human airway is continuously open to the non sterile environment where fungal spores have the potential to reach lung tissue and produce disease. Fungals infection are present in the environment and whose spores enter human (Puebla L.E.J, 2012). Depending on the virulence and pathogenecity there are broadly two types of fungi: true pathogenic fungi and opportunistic fungi (Ramana *et al*, 2013). Other fungal infections are said to be opportunistic because the causative agents cause mild or no disease in healthy individuals but may infect and cause severe disease in immunodeficient persons.

(Puebla L.E.J, 2012). Systemic fungal infections are a rarity that may result in high mortality (Ramana *et al*, 2013).

Invasive fungal infection was difficult to detect and diagnose because there was no clinical sign in oral cavity except patient systemic condition (Cortez *et al*, 2013). Invasive fungal infections (IFIs) are uncommon, but when they occur, they are devastating to patients (Fogarty *et al*, 2006). IFIs usually are seen in debilitated and immunosuppressed individuals. There are many reports of IFIs even in immunocompetent individuals thus making IFIs a potential threat in the present century (Ramani *et al*, 2013). These infections are

opportunistic, they occur when organisms to which we are frequently exposed gain entry to the body due to a decrease in host defenses or through an invasive portal, such as a dental extraction (Fogarty *et al*, 2006). Pandey *et al* (2011) report four cases of mucormycosis with exposed bone and all the patients gave a history of previous trauma due to self-extraction of a tooth or injection.

In the all cases report above, fungal infections were seen and affected the oral surgery with the pain in the gingival mucosa without any other signs of inflammation. The first patient was an immunocompromised condition where many were reported as a condition susceptible to fungal infections. Laihad FM (2017) reported the number of cases of diabetes mellitus associated with oral fungal infections. In 58 cases of mucormycosis infections triggered by tooth extraction, there are 41 cases with diabetes. More thorough examination is needed for diabetic's patients who require surgery in the oral cavity. The second and third cases are present in young and healthy patients without systemic abnormalities. The wound on the second patient's back hand indicate a fungal infection in the skin, so the possibility of an invasive fungal infection needs to be watch. In the third case obtained information that the patient often use antibiotics that allow the emergence of fungal infections (Osanky, 2012). All cases above previously received premedication antibiotic and analgetic because they were scheduled for minor surgery at the oral surgical clinic. The possibility of fungal infections in the all cases have become an invasive fungal infection based on an immunocompromised condition, the presence of wound on the back hand and the excessive antibiotics. Ramana *et al* (2013) said that the presence of fungal elements either as mould or yeast in deep tissues of biopsy or needle aspirates that is confirmed on culture and histo-pathological examination can be described as an Invasive Fungal infection (IFI). This suggest that the invasive fungal infections maybe or can be detected through the gingival mucosa in the oral cavity, so further research is required to prove this theory. Invasive fungal infections have an incidence that is much lower than superficial infections, yet invasive diseases are of greater concern because they are associated with unacceptably high mortality rates. Many species of fungi are responsible for these invasive infections, which kill about one and a half million people every year. In fact, at least as many, if not more, people die from the top 10 invasive fungal disease than from tuberculosis or malaria (Brown *et al*, 2012).

Oral candidiasis is the most common human fungal infection (Akpan & Morgan, 2002). *Candida spp* is an opportunistic fungi, that being a normal flora of human can be responsible for significant infections from superficial skin and nail infections to urinary tract infections and candidaemia (Ramana *et al*, 2013). Even though *Candida albicans* is the most common pathogen responsible for candidiasis, other *Candida species* causing oral infections have also been identified (Deepa *et al*, 2014). The results of fungal culture in the cases above possibly lead to *Candida* which usually considered as a normal flora in the oral mucosa (Akpan & Morgan, 2002; Raju & Rajappa, 2011). Using fluconazole as an antifungal prophylaxis can reduced the incidence of invasive *Candida* infections in many patients without the effect on mortality (Enoch *et al*, 2006). The positive reaction

from the administration of fluconazole in these cases indicated the presence of *Candida*.

The three cases above are part of 40 cases of fungal infections found in the oral surgery clinic of Naval Hospital dr Ramelan Surabaya Indonesia. These cases were found from April 2017 until November 2017 and the existence of these various cases makes the handling of patients in oral surgery needs more thorough examination.

4. Conclusion

It is necessary to watch out for fungal infections in patients with normal gingival mucosa who complain of pain during anesthesia and tooth extraction. Need to be aware of the presence of fungal infection when performing surgery in the oral cavity especially in immunocompromised patient, also in healthy patients and the possibility of spreading the infection to other organs through blood vessel. Further research is needed to ascertain the presence of fungi in the oral cavity that have been considered as a normal flora or even indicated as an invasive fungal infection.

References

1. Akpan A. and Morgan R., 2002. *Oral Candidiasis*. Postgraduate medical jurnal, volume 78, Issue 922.
2. Alfano C, Chiummariello S, Dessy LA, Bistoni G, Scuderi N., 2006. *Combine Mucormycosis and Aspergillosis of the Rhinocerebral Region*. In vivo 20:311-316
3. Brown GD, Denning DW, Gow NA, Levitz SM, Netea MG, White TC., 2012. *Hidden Killer: Human Fungal Infection*. Sci Transl Med 4, 165 Rv 13.
4. Cortez J, Gomes BC., Speidel A., Peixoto C., Selicka E., Valente C., Figueiredo P., Vieira A., 2013. *Mind the gap: Management of an emergent and threatening invasive fungal infection-a case report of rhino-orbital-cerebral and pulmonary mucormycosis*. Medical Mycology Case Reports volume 2, 2013, pages 79-84.
5. Deepa AG, Nair BJ, Sivakumar TT, Joseph AP., 2014. *Uncommon opportunistic fungal infections of oral cavity: A review*. Journal of Oral & Maxillofacial Pathology vol: 18/ Issue :2 / pages : 235 - 243
6. Enoch DA., Ludlam HA., Brown NM., 2006. *Invasive fungal infections: a review of epidemiology and management options*. Journal of Medical Microbiology;55:809-818
7. Fogarty C, Regennitter F, Viozzi CF, 2006. *Invasive fungal infection of the maxilla following dental extraction in a patient with chronic obstructive pulmonary disease*. J Can Dent Assoc;72(@):149-5
8. Laihad Fanny Margaretha, 2017. *Mucormycosis in the oral cavity with hyperbaric oxygen therapy*. Lambert Academic Publishing. ICS Morebooks, Balti, Republic of Moldova. p 26-27
9. Laihad FM, Mulawarmanti D, Parisihni K, Prameswari N, Revianti S, Widyastuti., 2017. *Periodontitis suspected caused by fungal infection*. International journal of current research , Vol 9, Issue 01, pp 45111-45114, January.
10. Osanky E, 2012. *The relationship between candida and Grave's disease*. Ezine articles.
11. Pandey A, Bansal V, Asthana AK, Trivedi V, Madan M, Das A., 2011. *Maxillary osteomyelitis by mucormycosis: report of four cases*. International journal of infectious disease volume 15, issue 1, pages e66-e69, January.

12. Puebla, L.E.J., 2012. *Fungal infections in immunosuppressed Patients*. Licensee In Tech.
13. Raju SB and Rajappa S., 2011. *Isolation and identification of Candida in The Oral Cavity*. ISRN.Dent ; 2011:487921. Oct 25 doi:10.5402/2011/487921
14. Ramana KV, Kandi S., Bharatkumar V., Sharada CH V., Rao R., Mani R., Rao SD., 2013. *Invasive Fungal Infections: A Comprehensive Review*. American Journal of Infectious Diseases and Microbiology 1.4(2013):64-69
15. Rickerts, V., Fredricks, D.N., 2012. *Tissue diagnosis of invasive fungal infections: Current limitations and the emerging use of molecular techniques*. Current Fungal Infections Reports, 6(3), pp. 221-228.